

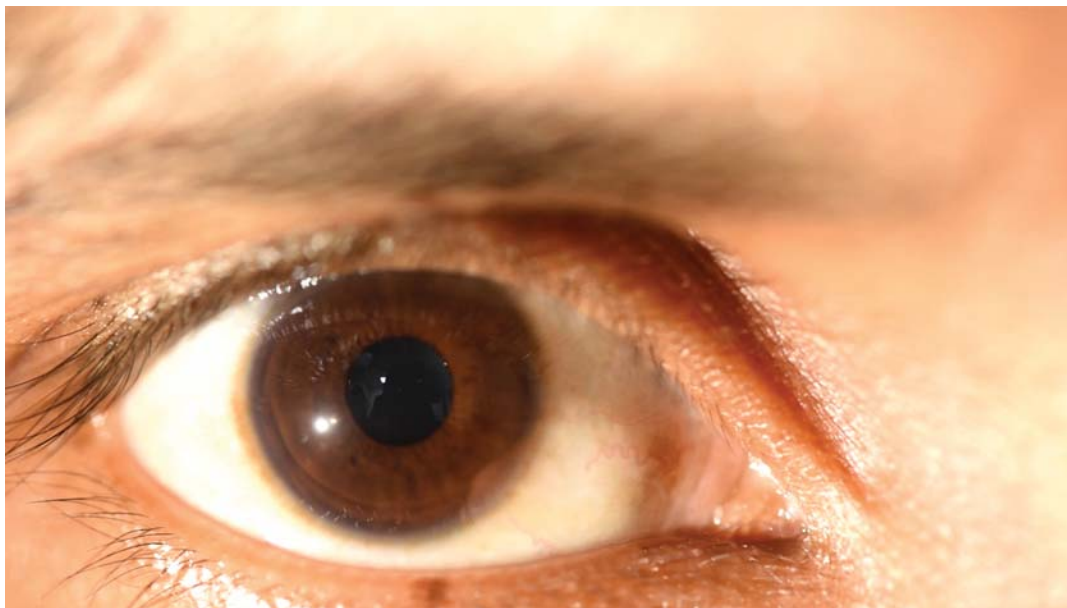
**Landolfi sign: Looking beyond what your eyes can see**

FIG 1. Landolfi sign

A 21-year-old man presented with complaints of fever and palpitations of 2 weeks' duration. On examination, the blood pressure was 140/60 mmHg, pulse 120 beats/minute, respiratory rate 20/minute and SpO<sub>2</sub> 98%. A diastolic decrescendo murmur was heard along the left upper sternal border. On ocular examination, an alternate constriction and dilatation of the pupil with each heartbeat was seen (See video at [www.nmji.in](http://www.nmji.in)). This is due to an increased stroke volume and wide pulse pressure in the iridial vessels and is a classical finding of severe aortic regurgitation. Transthoracic 2D echocardiography showed severe aortic regurgitation with a 10 mm vegetation on the right coronary cusp and aneurysmal dilatation of the sinus of Valsalva. Computed tomography scans revealed an unruptured 4×4 cm aneurysm of the sinus of Valsalva. The patient underwent aortic valve replacement and repair of the aneurysm of the sinus of Valsalva using Gortex patch and then received intravenous antibiotics. He tolerated the treatment well and has been discharged in an afebrile and haemodynamically stable condition.

DEVESH CHAUDHARY, SATYAVIR YADAV

*Department of Cardiology, All India Institute of Medical Sciences, New Delhi, India  
drsatyaviryadav87@gmail.com*

[To cite: Chaudhary D, Yadav S. Landolfi sign: Looking beyond what your eyes can see. *Natl Med J India* 2024;37:51. DOI: 10.25259/NMJI\_1070\_2022]