

## Images in Medicine

### Hamman syndrome

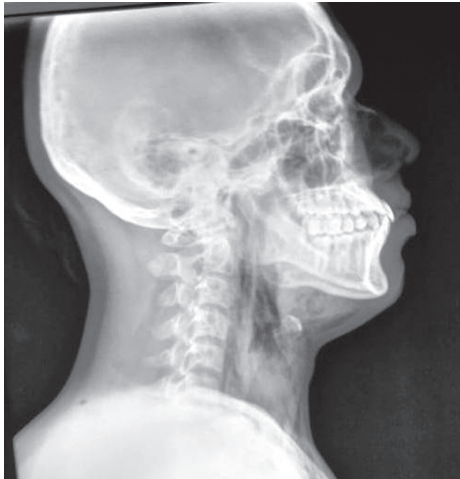

FIG 1. X-ray neck lateral view showing subcutaneous emphysema

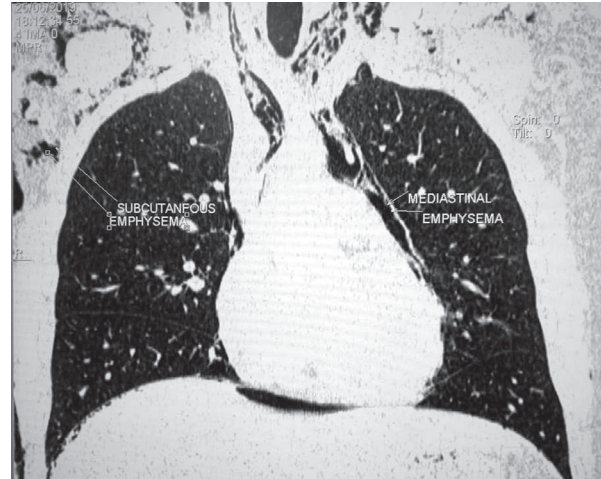


FIG 2. Non-contrast computed tomography chest showing subcutaneous emphysema and pneumomediastinum

A 19-year-old male, without any previous comorbid conditions, presented to the emergency department with a history of swelling in the neck, hoarseness of voice and fever for 1 day. Clinically, he had tachycardia, and there was crepitation in the neck and anterior chest wall on palpation. His past medical history was non-contributory, and he was not on any medication. He denied any history of trauma, surgery or any medical procedure. On chest X-ray posteroanterior view, subcutaneous emphysema was confirmed. Non-contrast computed tomography of the chest showed mediastinal and subcutaneous emphysema but no pneumothorax (Figs 1 and 2). Bronchoscopy and oesophagoscopy revealed no abnormality. Electrocardiogram showed sinus tachycardia. He was observed in the intensive care unit on 100% oxygen support, and the subcutaneous emphysema gradually resolved over 72 hours. Hamman syndrome (spontaneous pneumomediastinum presenting as subcutaneous emphysema), often idiopathic, is a rare clinical entity. Its incidence is <1:44 000, with a male predominance.<sup>1</sup> Patients can present with thoracic pain, dyspnoea, swelling in the neck, dysphagia, fever or hoarseness of voice. Conservative management is required with follow-up.<sup>2</sup> It is a benign entity with good prognosis. Drainage of subcutaneous air by a microdrainage catheter or skin incisions may be required in symptomatic patients with respiratory distress.

*Conflict of interest.* None declared

#### REFERENCES

- 1 Kouritas VK, Papagiannopoulos K, Lazaridis G, Baka S, Mpoukovinas I, Karavasilis V, *et al.* Pneumomediastinum. *J Thorac Dis* 2015;7:S44–S49.
- 2 Jougon JB, Ballester M, Delcambre F, Mac Bride T, Dromer CE, Velly JF, *et al.* Assessment of spontaneous pneumomediastinum: Experience with 12 patients. *Ann Thorac Surg* 2003;75:1711–14.

J. SANKAR  
sankarjayaprakash@gmail.com  
Department of Medicine

MANEESH UNİYAL  
Department of Radiodiagnosis, Military Hospital, Chennai, Tamil Nadu

KISHORE KUMAR  
Department of Medicine and Oncology, Command Hospital, Bengaluru, Karnataka