

A rare side-effect of fluoroquinolones

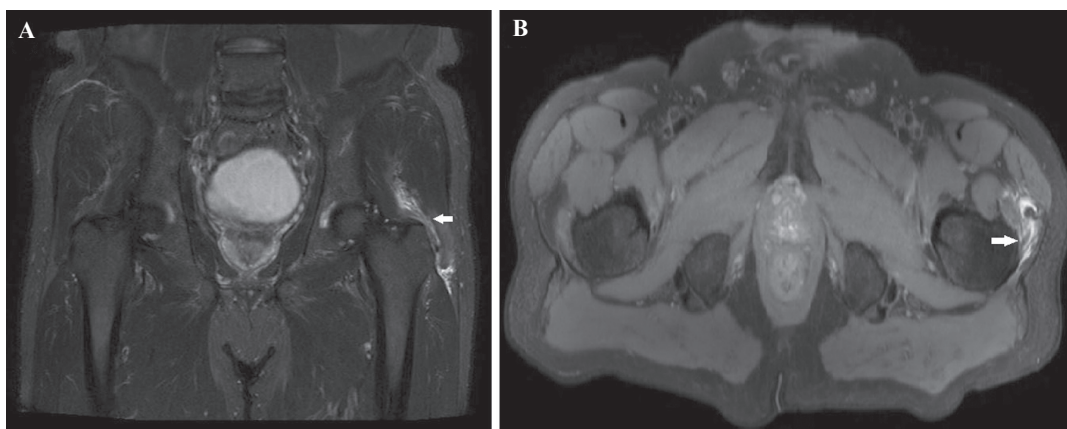


FIG 1. MRI bilateral hip region: Coronal image (A: short inversion time inversion recovery sequence) and axial image (B: proton density fat-sat sequence) showed mild-to-moderate hyperintensity involving tendons of the left gluteus medius and gluteus minimus near the insertion site at greater trochanter (marked by arrows) suggestive of tendinitis

A 61-year-old male presented with complaints of pain over the left greater trochanter along with limping for 2 days. He had no other comorbid conditions including joint or tendon problems. There was no history of trauma. He had taken levofloxacin for an upper respiratory tract infection for 3 days before the onset of the above symptoms. He was not on any long-term medication including steroids. Physical examination revealed tenderness over the left greater trochanter but without erythema. MRI bilateral hip region (Fig. 1) showed mild-to-moderate hyperintensity involving tendons of the left gluteus medius and gluteus minimus near the insertion at the greater trochanter (marked by arrows) suggestive of tendinitis. It was diagnosed as levofloxacin-induced tendinitis due to the temporal relationship and absence of other causes (Naranjo scale score was 7: probable adverse drug reaction). Levofloxacin was stopped and he recovered fully within 10 days.

Fluoroquinolone-induced tendinopathy or tendon rupture is a rare side-effect, occurring in 0.14%–0.4% of otherwise healthy controls.¹ Ciprofloxacin and pefloxacin are the usual culprits; however, levofloxacin, ofloxacin and norfloxacin can also cause tendinopathy. Achilles' tendon is the most commonly affected site in about 90% of patients. Although the mean time of onset of symptoms of tendinopathy is around 2 weeks after initiation of the offending drug, it can occur as early as 2 hours to as late as 6 months after starting the drug.²

Conflicts of interest. None declared

REFERENCES

- 1 Tsai WC, Yang YM. Fluoroquinolone-associated tendinopathy. *Chang Gung Med J* 2011;**34**:461–7.
- 2 Tam PK, Ho CT. Fluoroquinolone-induced Achilles tendinitis. *Hong Kong Med J* 2014;**20**:545–7.

SANJEEV KAPOOR
Department of Internal Medicine

KAMAL GERA, GURMEET SINGH CHABBRA
Department of Respiratory Medicine
QRG Health City, Faridabad, Haryana, India
kamalgera36@gmail.com