

Images in Medicine

Double globes in single-orbit sign

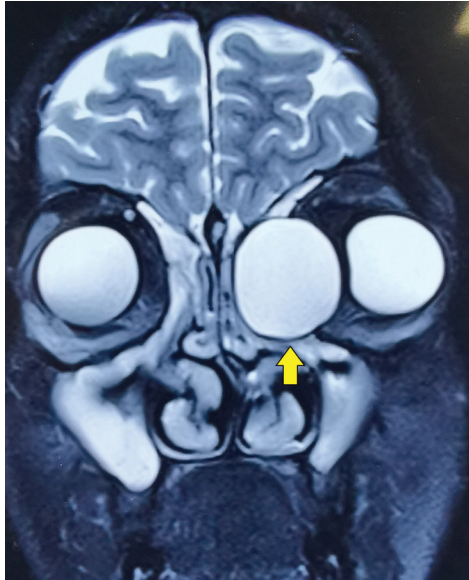


FIG 1. MRI showing a hyperintense cystic lesion on T2-weighted imaging at the left medial canthus, giving the appearance of 'the double globe in single-orbit' or 'the third eyeball' sign

A 19-year-old man presented with complaints of outward displacement of the left eyeball for the past 2 years. On examination, the left eyeball had lateral dystopia of 6 mm. On T2-weighted MRI, a well-defined cystic lesion in the left orbit, resembling the other globe, was seen (Fig. 1). CT scan revealed a heterogeneous lesion in the left fronto-ethmoid sinus with extension into the orbit. A provisional diagnosis of left fronto-ethmoidal mucocoele was made. He underwent surgical removal of the mucocoele, and the affected ethmoid sinus was connected to the nasal cavity.

Mucocoeles are epithelial-lined cystic lesions frequently located in the paranasal sinuses. Their pathogenesis remains a mystery and many believe the cause to be a sequelae of obstruction of the affected sinus due to chronic rhinosinusitis, trauma or surgery.¹ The presenting symptoms usually include headache, recurrent episodes of nasal obstruction, diplopia, displacement of the ocular globe and in severe instances, meningitis.² Mucocoeles in the fronto-ethmoid sinus displace the eyeball forwards, downwards and laterally. The investigation of choice is CT scan, as it provides details of the bony erosions and orbital and intracranial extensions. On T2-weighted MRI, these appear as well-defined cystic lesions and can mimic the globe, giving the appearance of double globes in a single orbit.³ Malignant lesions, dermoid cysts, fungal and tubercular granulomas and cholesterol granulomas form the list of differential diagnoses. The management of fronto-ethmoidal mucocoeles primarily involves surgical excision with marsupialization.⁴

Conflicts of interest. None declared

REFERENCES

- 1 Bakshi SS. Image diagnosis: Frontoethmoidal mucocoele. *Perm J* 2019;**23**:18–288.
- 2 Scangas GA, Gudis DA, Kennedy DW. The natural history and clinical characteristics of paranasal sinus mucocoeles: A clinical review. *Int Forum Allergy Rhinol* 2013;**3**:712–17.
- 3 Stokken J, Wali E, Woodard T, Recinos PF, Sindwani R. Considerations in the management of giant frontal mucocoeles with significant intracranial extension: A systematic review. *Am J Rhinol Allergy* 2016;**30**:301–5.
- 4 Courson AM, Stankiewicz JA, Lal D. Contemporary management of frontal sinus mucocoeles: A meta-analysis. *Laryngoscope* 2014;**124**: 378–86.

SAHIL AGRAWAL, SUJEETH MODABOYINA, AISHWARYA RATHOD, DEEPEKHAR DAS
*Dr Rajendra Prasad Centre for Ophthalmic Sciences
 All India Institute of Medical Sciences, New Delhi, India
 doc.deep.das@gmail.com*