

## Spontaneous resolution of a wooden foreign-body granuloma in the conjunctiva of a child

SIDDHARTH MADAN, SARITA BERI, NISHANT YADAV

### ABSTRACT

A conjunctival foreign-body (FB) granuloma may result following trauma with synthetic and non-synthetic materials including organic and non-organic objects. Children usually manifest with FB granulomas that develop due to inoculation of FBs from soft toys, blankets or woollen clothes. Encapsulation of these FBs following a granulomatous inflammatory response results in a nodular swelling in the conjunctiva. Reports of a wooden FB granuloma in the conjunctiva in children are anecdotal. A 5-year-old boy suffered an un-witnessed direct ocular trauma to his left eye (OS) with a wooden arrow while playing. He developed redness and nodular swelling at the inferotemporal aspect of the OS without any visual complaints. The diagnosis of a wooden FB granuloma is a challenge to ophthalmologists and may go undetected in children who neglect their symptoms. It characteristically presents as a unilateral conjunctival nodule. Surgical excision is the definitive management. However, spontaneous extrusion of the FB might be observed due to protective blinking and tearing mechanisms in the eye.

Natl Med J India 2023;36:231–2

### INTRODUCTION

Penetrating eye injuries commonly occur following accidents, assaults, war, etc. and the inciting object causing trauma could be unusual. A foreign body (FB) can lodge in the eye, orbit and/or brain. The literature following trauma with a wooden object resulting in an FB granuloma in the conjunctiva of a child is sparse. Moreover, a strong suspicion of the same is necessary to prevent misdiagnosis and start appropriate management.

### THE CASE

A 5-year-old boy suffered an un-witnessed direct trauma to his left eye (OS) in the morning while playing with his brother at home. Following the injury, he developed redness at the inferotemporal aspect of the OS without any accompanying diminution of vision or much pain. The mother consulted an ophthalmologist in the evening. A presumptive diagnosis of phlyctenular conjunctivitis was made as a small painless red nodular swelling was seen at the site of trauma. Medical

treatment with topical ofloxacin and dexamethasone eye drops four times in a day was started. On review 5 days later, the redness persisted and the nodule had increased in size. Oral amoxicillin and clavulanic acid were prescribed, and the child was referred to a higher centre. At presentation, his unaided visual acuity was 6/9 (both eyes, OU). His best-corrected visual acuity was 6/6 OU. On examination, a 3 mm×1.5 mm, pale, elevated nodular lesion was seen 3 mm inferotemporal to the limbus. There was marked prominence of the overlying conjunctival and episcleral vessels; these were dilated and tortuous. Anterior segment examination, ocular motility and intraocular pressure were normal and so was the central and peripheral fundus. The procedure of scleral indentation was done under sedation after consultation with a paediatrician. A diagnosis of a wooden FB granuloma due to an impacted conjunctival FB or a pyogenic granuloma was presumed. An X-ray orbit ruled out the presence of an FB. Ultrasound B-scan did not show an FB either and revealed an anechoic posterior segment. In the meantime, topical treatment with fluorometholone eye drops thrice a day and moxifloxacin eye drop four times a day was advised and the child was reviewed a week later. The redness and nodule persisted. Magnetic resonance imaging (MRI) of the orbit was scheduled 5 days later. However, the radiologist suggested doing a non-contrast CT scan before the MRI to rule out a metallic FB. While undergoing investigations on review, the mother reported spontaneous extrusion of a wooden FB that was small and linear measuring 2 mm in length, the picture of which she captured on her phone and carried with her. She said the child was crying excessively before the FB extrusion, complaining of a pricking sensation in his eyes. However, there was no history of excessive rubbing of the eye at that time. The nodule at the site of trauma

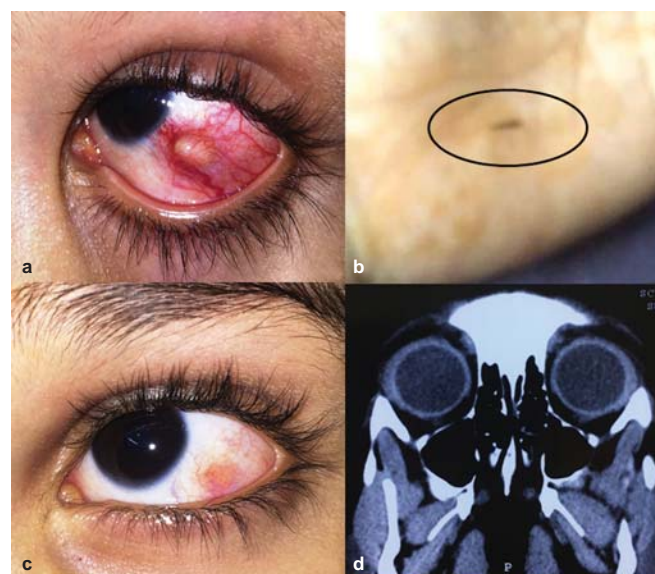


FIG 1. The child at presentation with a 3 mm×3 mm nodule at the inferotemporal aspect of the eye located 3 mm from the limbus (a). The nodule showed overlying conjunctival congestion with dilated episcleral vessels. A wooden foreign body (about 2 mm in length) spontaneously extruded out of the eye, picture of which was captured by the mother of this child in her phone (b). The redness reduced and the nodule flattened after foreign body extrusion (c). Non-contrast computed tomography scan done after foreign body extrusion was normal (d)

Lady Hardinge Medical College and Associated Hospitals, University of Delhi, New Delhi, India

SIDDHARTH MADAN, SARITA BERI, NISHANT YADAV  
Department of Ophthalmology

Correspondence to SIDDHARTH MADAN;  
drsiddharthmadan@gmail.com

[To cite: Madan S, Beri S, Yadav N. Spontaneous resolution of a wooden foreign-body granuloma in the conjunctiva of a child. *Natl Med J India* 2023;36:231–2. DOI: 10.25259/NMJ1\_562\_20]

© The National Medical Journal of India 2023

had flattened and redness had reduced. Topical steroids and antibiotics were continued. Subsequently, the child underwent a non-contrast computed tomography (NCCT) scan that was normal. The MRI was deferred. Currently, the boy is doing well.

#### DISCUSSION

Injury to the eye and orbit occurs following high-velocity craniofacial trauma often in young people. The agent causing trauma might be a household object,<sup>1</sup> which could be metallic, inorganic, non-metallic or organic such as plant, thorn, vegetable matter or wood.<sup>2</sup> Injuries with wooden FB are more often seen in farmers and agriculture workers in rural parts of India.<sup>3</sup> Wooden FB injuries occur with entry sites at the upper lid and inner or outer canthus without any apparent ocular damage.<sup>4</sup> Plant-based conjunctival FBs can lead to infection with phaeohyphomycosis and may mimic a depigmented inflammatory naevus.<sup>5</sup> Another differential diagnosis of a conjunctival nodule could be nodular episcleritis; however, there was no underlying systemic history that gave a pointer to its occurrence. Penetration by a wooden FB via the transorbital region into the intracranial cavity following trivial injuries is unusual but has been reported.<sup>6</sup>

X-rays do not detect a wooden FB. It is difficult to detect the same on CT scans, as the density of wood is similar to that of soft tissues of the orbit and the intracranial cavity. The properties of wood get altered more when it is present in an aqueous environment for about 48 hours during which it imbibes water. However, an orbitocranial wooden FB has been successfully shown on CT scan.<sup>7</sup> Dry wooden FBs and those surrounded by air are often not detected on ultrasound.<sup>8</sup> MRI is the investigation of choice when a retained wooden FB is suspected. However, detection of the edge and delineating the shape of the FB might be difficult with MRI. If the FB has ferromagnetic substances, subjecting the patient to MRI can be disastrous as an intraocular metallic FB can lead to visual loss and vitreous haemorrhage. Considering economic factors, a time-consuming MRI procedure necessitating patient coöperation or a general anaesthesia/sedation in a child and common availability of CT scan units, a CT scan of brain and orbit might be considered on emergent basis in children. Depending on an imaging-based diagnosis can often be misleading. A thorough history and examination is mandatory, which should be assisted by radiological investigations. A strong suspicion must exist about a wooden

FB in a child with an accident or an un-witnessed trauma in the countryside fields and more so when there is a definitive history of a trauma with a wooden object.<sup>9</sup>

Retained intraocular wooden FBs may complicate into a chronic draining fistula, abscess, endophthalmitis, granuloma, orbital cellulitis or even blindness.<sup>10</sup> Prior initiation of antibiotic therapy is mandatory in all perforating orbital injuries with wooden FBs as wood serves as a potentially dangerous reservoir of microorganisms, especially fungi. Surgical exploration for a retained FB becomes important as medical management may not suffice. Usually, unexplained loss of vision accompanied with severe pain, redness and swelling near the site of ocular trauma points to the presence of an FB. However, an extraocular FB might manifest with swelling and redness without accompanying visual loss, and presentation to an ophthalmologist might be delayed. The spontaneous extrusion of an anteriorly placed sub-conjunctival FB as in rare case scenarios as in this patient where documented evidence of FB extrusion and prompt imaging averted the need for general anaesthesia and consider an alternative diagnosis for the presenting clinical manifestations.

*Conflicts of interest.* None declared

#### REFERENCES

- 1 Turliuc DM, Costan VV, Cucu AI, Costea CF. Intraorbital foreign body. *Rev Med Chir Soc Med Nat Iasi* 2015;**119**:179–84.
- 2 Moretti A, Laus M, Crescenzi D, Croce A. Peri-orbital foreign body: A case report. *J Med Case Rep* 2012;**6**:91.
- 3 Mohapatra SS, Das J, Bhattacharjee H. An unusual case of orbitocranial wooden foreign body with amazing outcome: A case report. *Indian J Ophthalmol* 2020;**68**:219–21.
- 4 Bursick DM, Selker RG. Intracranial pencil injuries. *Surg Neurol* 1981;**16**:427–31.
- 5 Maudgil A, Johnson Z, Rogers N, Mudhar HS. Unusual ocular presentations of ocular phaeohyphomycosis. *Eye (Lond)* 2016;**30**:1517–19.
- 6 Brock L, Tanenbaum HL. Retention of wooden foreign bodies in the orbit. *Can J Ophthalmol* 1980;**15**:70–2.
- 7 Dudani A, Pawar H, Dudani AA, Dudani K, Dudani A. A challenging case of a large orbitocranial wooden foreign body in a child. *Indian J Ophthalmol* 2019;**67**:1510–12.
- 8 Mitilian D, Charon B, Brunelle F, Di Rocco F. Removal of a chopstick out of the cavernous sinus, pons, and cerebellar vermis through the superior orbital fissure. *Acta Neurochir (Wien)* 2009;**151**:1295–7.
- 9 Mirzaei F, Salehpour F, Shokuhi G, Asvadi Kermani T, Salehi S, Parsay S. An unusual case of intra orbital foreign body; diagnosis, management, and outcome: A case report. *BMC Surg* 2019;**19**:76.
- 10 Lee JS, Lee JE, Oum BS, Cha SH. Orbitocranial injury caused by wood. *Korean J Ophthalmol* 1999;**13**:128–32.