

Images in Medicine

Fluid waves in anterior chamber: A sign of intra-vitrectomy zonular weakness

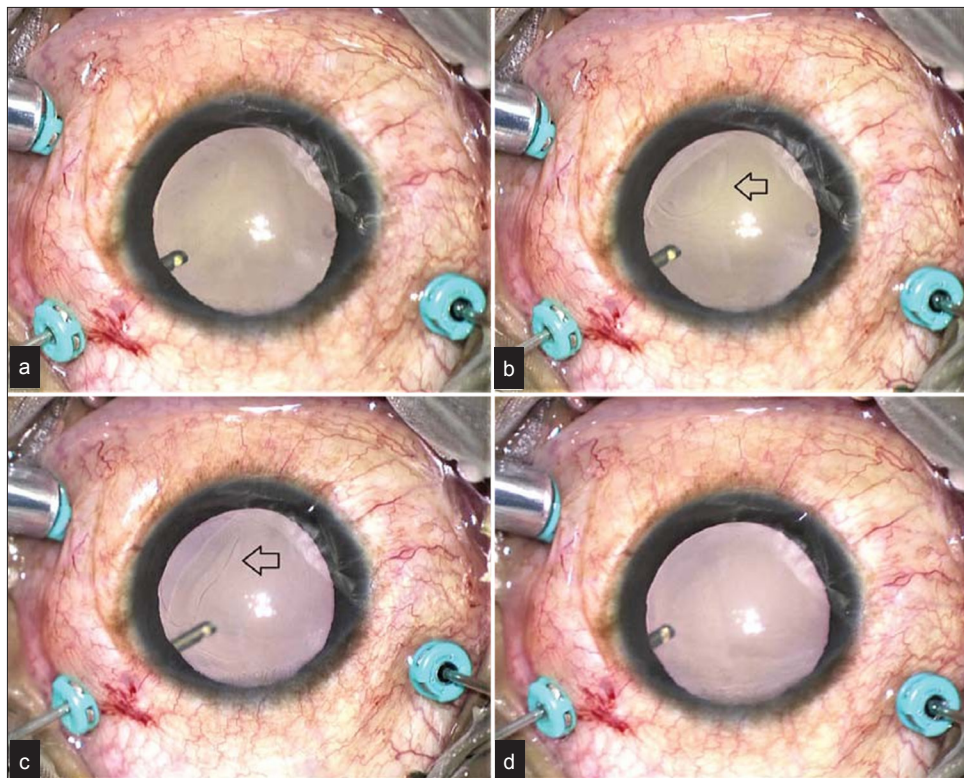


FIG 1. (a) Vitrector and suction off; (b, c) vitrector and suction on, fluid waves seen (arrow); (d) vitrector and suction turned back off, the waves disappear

A 25-year-old otherwise healthy male had rhegmatogenous retinal detachment as a sequela of blunt injury to his right eye. During pars plana vitrectomy, fluid waves were seen in the anterior chamber whenever the vitrector was turned on with suction (Fig 1. a–d). This turned on the fluid through the infusion port into the posterior segment, which was apparently leaking into the anterior chamber clinically seen as the fluid waves (likely because of traumatic insult to lenticular zonules¹ as well at the time of blunt injury). The waves were inferred to be in the anterior chamber supported by the fact that they were seen through the operating microscope most clearly in the same plane as other anterior chamber structures. We propose this to be an indirect intraoperative sign of zonular weakness in our patient.

REFERENCES

- 1 Rai G, Sahai A, Kumar PR. Outcome of capsular tension ring (CTR) implant in complicated cataracts. *J Clin Diagn Res* 2015;9:NC05–NC07.

Amber Amar Bhayana, Pradeep Venkatesh

Dr Rajendra Prasad Centre for Ophthalmic Sciences All India Institute of Medical Sciences, New Delhi, India

amber.amar.bhayana@gmail.com

[To cite: Bhayana AA, Venkatesh P. Fluid waves in anterior chamber: A sign of intra-vitrectomy zonular weakness. *Natl Med J India* 2025;38:187. DOI: 10.25259/NMJI_1062_2022]