

How to do it

Safe insertion of a chest tube

ARVIND KUMAR, ROMAN DUTTA, TARUN JINDAL, BHABATOSH BISWAS,
RAVINDRA KUMAR DEWAN

INTRODUCTION

Insertion of a chest tube is the procedure of placing a flexible, hollow drainage tube into the chest to remove an abnormal collection of air or fluid from the pleural space so as to enable the lungs to expand completely. It is the commonest chest emergency encountered by general surgeons. Sometimes, in acute situations, even physicians may be required to perform the procedure as a 'life-saving' measure. Hence, we feel that doctors in all specialties should be able to insert a chest tube safely.

INDICATIONS

The following are the common indications for which a chest tube is placed.

1. Pneumothorax
 - Primary spontaneous pneumothorax (persistent or recurrent, after simple aspiration)
 - Secondary spontaneous pneumothorax
 - Tension pneumothorax (after initial needle aspiration)
 - In any ventilated patient
2. Malignant pleural effusion
3. Empyema and complicated para-pneumonic pleural effusion
4. Traumatic haemo-pneumothorax
5. Postoperative, e.g. after oesophageal, cardiac, pulmonary, mediastinal or pleural surgery
6. Treatment with sclerosing agents or pleurodesis
7. Post-pneumonectomy bronchopleural fistula

CONTRAINDICATIONS

1. Lung adherent to the chest wall is an absolute contraindication.
2. Uncorrected coagulopathy is a relative contraindication if the procedure needs to be done in an elective situation.

STEPS OF THE PROCEDURE

Pre-insertion evaluation

Careful clinical evaluation of the patient is necessary to assess the need for placement of a chest tube. Thereafter, the patient's chest X-ray, ultrasound or CT scan should be carefully examined and if

any clarifications are required, discussed with the radiologist.¹ It is prudent to rule out a lung bulla before inserting a chest tube as it may mimic a pneumothorax. Having decided that a chest tube needs to be inserted, the procedure should be carefully explained to the patient and/or his or her relatives. They should be informed about the risks, benefits and possible complications. The fact that, in a given situation, there is no alternative to the insertion of a chest tube should also be explained. This is an important step and often overlooked in emergency situations. A detailed explanation of the steps of the procedure help in soliciting the patient's cooperation and is crucial in ensuring the overall safety and success of the process. The informed consent of the patient should be obtained after the procedure has been explained to him/her. The site of the abnormality should be verified on the chest X-ray of the patient by at least 2 members of the team involved in the procedure. The site can be marked on the patient's chest to prevent the insertion of the chest tube on the wrong side.

If the patient is apprehensive, it is advisable to give a mild sedative. An intravenous line must always be in place to give intravenous fluids or any intravenous medication. Attempting to insert a chest tube without providing for intravenous access is asking for trouble. It is advisable to monitor the patient's oxygen saturation during the insertion of the chest tube.

Choosing the site of insertion

The next step is to choose the site of insertion. The exact site depends on the location of the abnormality. However, if the chest tube is being inserted for pleural effusion or haemo-pneumothorax, the most common scenarios, the fifth intercostal space in the mid-axillary line is the site used most often. It was earlier believed that air can be drained only through an anteriorly placed tube in the second intercostal space. However, experience has shown that a tube of the proper size, inserted through the fifth intercostal space in the mid-axillary line, can drain air equally effectively. Even if one does insert a chest tube in the second intercostal space, it should be in the mid-clavicular line. A tube placed too medially may injure the internal mammary artery, causing serious haemorrhage.

In cases of loculated pleural effusion, empyema or pneumothorax, it is a good practice to do an ultrasound, with the patient in a sitting posture, to find the lowest level of fluid and also, to perform an ultrasound-guided needle aspiration to confirm the exact site of insertion of the chest tube.² Having aspirated fluid through the needle, the chest tube can be put at the site of the needle puncture in the radiology suite, or the site can be marked and the patient brought back to the ward for the procedure. An ultrasound-guided diagnostic aspiration is very helpful in choosing the optimal site of insertion of the chest tube in patients with a

All India Institute of Medical Sciences, Ansari Nagar, New Delhi 110029, India

ARVIND KUMAR, ROMAN DUTTA, TARUN JINDAL
Department of Surgical Disciplines

R.G. Kar Medical College, Kolkata, West Bengal, India

BHABATOSH BISWAS Department of Cardiothoracic Surgery

L.R.S. Institute for TB and Allied Sciences, New Delhi, India

RAVINDRA KUMAR DEWAN Department of Thoracic Surgery

Correspondence to ARVIND KUMAR; arvindreena@hotmail.com

© The National Medical Journal of India 2009

loculated collection, as blind insertion may not always ensure correct placement of the tube. This exercise is never possible in an emergency situation and is not required in patients with generalized effusion or haemo-pneumothorax. The ‘safe triangle’, an area bordered by the anterior border of the latissimus dorsi, the lateral border of the pectoralis major, a line superior to the horizontal level of the nipple, with its apex towards the axilla, is the usual site which corresponds to the fifth or sixth space in the mid-axillary line.

Instruments and material required

A chest tube of an appropriate size and type is required. The available chest tubes are straight or angled simple tubes, or those with a metallic trocar inside. Many times, a Malecot catheter is used as a chest tube (Fig. 1). Most commonly, straight tubes are used and these are available in sizes 16 Fr to 38 Fr. The angled tube is generally used in the postoperative setting. The trocar chest tube is helpful in draining loculated collections as the trocar helps direct the chest tube to the desired location. The size of the chest tube depends on the abnormality. For a pneumothorax in an adult, a 22 Fr or 24 Fr tube will suffice. However, for haemothorax, a 28 Fr or 30 Fr tube is preferred. For younger individuals and children, a tube of an appropriately smaller size may be used. It is preferable to keep an extra chest tube available at the time of insertion, should the one being used get spoilt during the procedure for any reason.

The other material required includes a minor procedure set (Fig. 2), consisting of a sponge holder, a bowl and enough gauze pieces for cleaning, a scalpel handle with a 15 no. blade, 2 long artery forceps (Kelly forceps), a toothed tissue forceps, a needle holder and suture cutting scissors, 4–6 sterile towels and a skin fixation suture (No. 1 silk on a curved cutting needle).

Antiseptic solutions, such as Savlon, betadine and spirit, are needed for skin preparation. The other requirement is an underwater drainage system. Commercially available single- or dual-chamber chest tube drainage bottles are preferred (Figs 3a and 3b). Alternatively, a saline bottle improvised to have an underwater seal (Fig. 3c) or a chest drainage bag (Fig. 3d) can be used, depending on availability. The bottle should be filled with saline up to the marking. All the connections should be done and the drainage tube should be kept ready in the sterile field to be connected to the chest tube as soon as the latter is in position (Fig. 4).

Position of the patient

A chest tube can be inserted in the supine, sitting or lateral position. The most preferred is the supine position, in which the patient lies flat on the bed, slightly rotated to the opposite side, with the ipsilateral arm behind her/his head so as to expose the axillary area (Fig. 5).³ Patients who are breathless may be uncomfortable in the supine position and may, therefore, be asked to sit upright in the bed, leaning over a cardiac trolley with a pillow




FIG 1. Chest tubes: (a) angled; (b) straight; (c) Malecot catheter; (d) assembled trocar chest tube and (e) its tube; and (f) metallic trocar

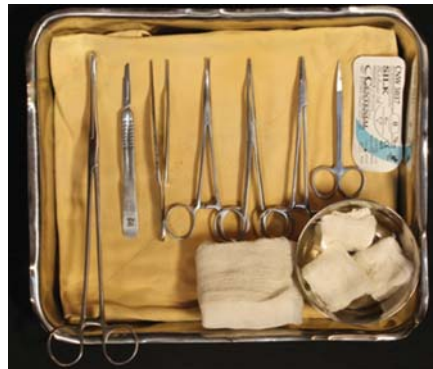

FIG 2. Minor procedure set with instruments




FIG 3. Pleural drainage system: (a) double-chamber; (b) single-chamber; (c) improvised saline bottle; (d) pleural drainage bag

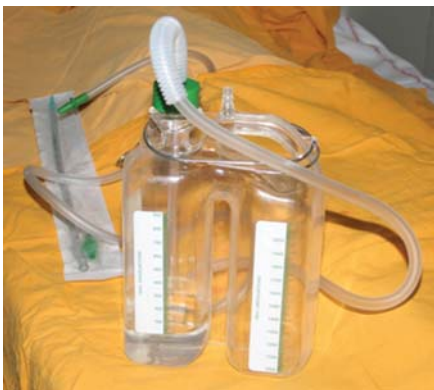

FIG 4. Chest tube and pleural drainage system kept ready

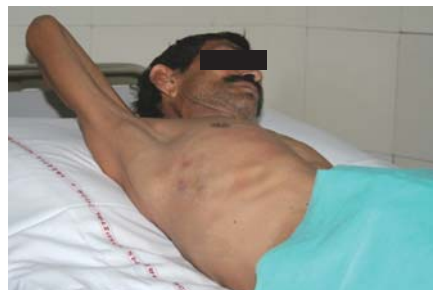

FIG 5. Position used most often for chest tube insertion: Supine, slightly rotated to the opposite side with the ipsilateral arm under the head

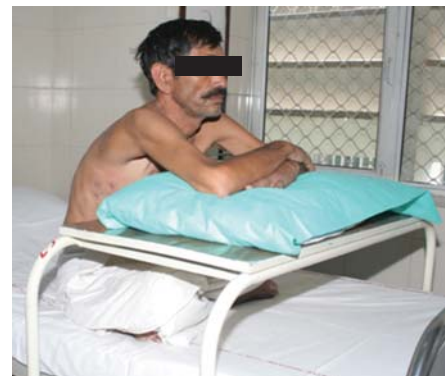

FIG 6. Sitting position with the patient leaning over the cardiac trolley

to place their arms on (Fig. 6). The lateral decubitus position is occasionally used, particularly for loculated collections situated posteriorly.⁴

Cleaning and draping

Strict aseptic techniques should be used while inserting the chest tube so as to avoid iatrogenic infection. The person doing the procedure should scrub and don the attire worn in an operating room (Fig. 7). The patient's skin should be prepared from the axilla to the iliac crest and from the nipple line to the midline posteriorly (Fig. 8). Thereafter, the area should be draped with sterile towels on all sides, leaving only a few inches exposed on either side of the proposed site of insertion (Fig. 9). It is necessary to prepare and drape a wide area so that asepsis is not breached during the procedure. It is not uncommon to see pleural effusions turning into empyema following the insertion of a chest tube due to failure to perform the procedure in an aseptic manner.

Local anaesthesia

At the site of insertion, a local anaesthetic is injected through the skin into the subcutaneous tissue, muscle and up to the pleura (Fig. 10). It is important to insert the needle slowly to prevent inadvertent injury to the lung. It is also important to inject the drug in different directions to anaesthetize an area wider than the size of the chest tube to ensure a painless procedure.

Incision and insertion of the tube

A skin incision is made which is slightly bigger than the diameter of the chest tube. Those who do not insert chest tubes routinely

should make a skin incision that is large enough for them to be able to feel the intercostal space without difficulty. With blunt dissection using an artery forceps, adequately guarded by the fingers of the doctor's left hand, a tunnel is created down to the pleural cavity at the upper border of the lower rib in the chosen intercostal space (Figs 11–13).^{3,5,6} It is vital to keep the artery forceps guarded with the fingers of the opposite hand to prevent their sudden entry into the pleural cavity. Sudden entry of the forceps can injure structures inside (Fig. 14) the pleural cavity and lead to serious consequences. The feel of a pleural puncture is like that of puncturing a balloon filled with water, as if something has given way. Next, the artery forceps should be gently opened in one direction and then again at right angles to dilate the tract, so that the chest tube can be inserted (Figs 15 and 16). It is important to keep the artery forceps in an open position for a few seconds to allow the tract to be adequately dilated. During this step, the patient should be asked to stop breathing so as to prevent air from rushing into the pleural cavity. The creation of a tract of adequate diameter up to the pleural cavity ensures that excessive force is not needed during insertion of the chest tube. The physician inserting the chest tube should place a finger through the tunnel into the pleural cavity and feel for any adhesions between the parietal pleura and the lung parenchyma. Thereafter, the chest tube should be held by the artery forceps just proximal to its tip and inserted through the just created tract (Fig. 17). The artery forceps should be used to ensure the entry of the tip of the chest tube into the pleural cavity and should be withdrawn thereafter. An appropriate length of the chest tube can now be pushed inside in the desired direction (Figs 18 and 19). During the insertion of a chest tube in a patient on a

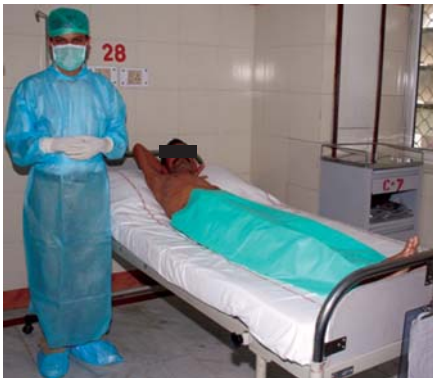

FIG 7. Aseptic precautions: The attire of the doctor inserting the chest tube. The preparation of the patient should be akin to the process followed in an operation theatre

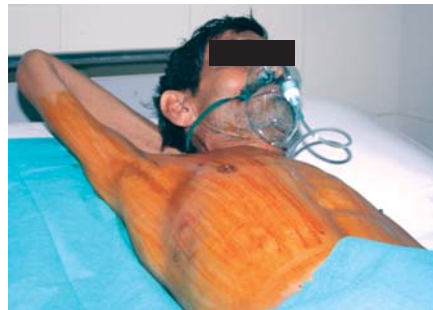

FIG 8. Skin preparation. A wide area is cleaned and prepared (usually with Savlon, followed by painting with 10% povidone iodine)

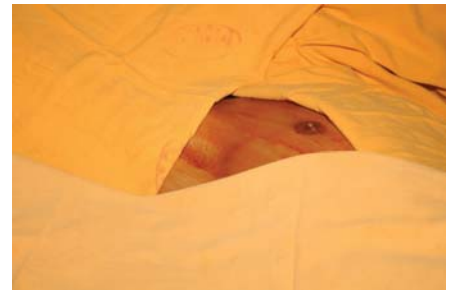

FIG 9. Draping: Sterile drapes are placed around the site of insertion of the tube

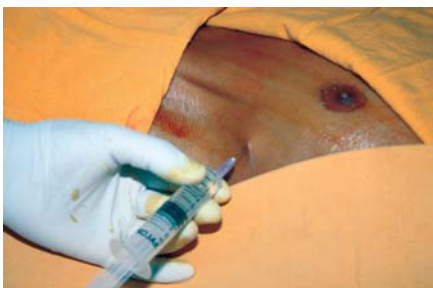

FIG 10. Local anaesthesia: The site of insertion is infiltrated with local anaesthetic

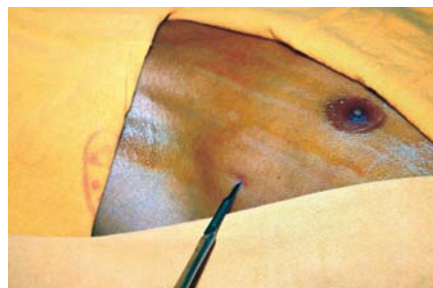


FIG 11. Skin incision: A no. 15 blade is used to make the skin incision

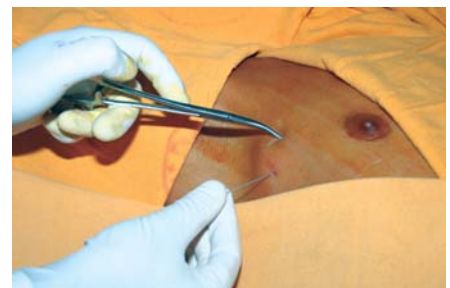

FIG 12. Planning the subcutaneous tunnel: The direction of the subcutaneous tunnel for inserting the chest tube. The tip of the needle shows the skin incision site, whereas the tip of the artery forceps shows the site of puncture on the chest wall

ventilator, especially with positive-end expiratory pressure (PEEP), it is essential to disconnect the ventilator at the time of insertion so as to avoid injury to the lung.⁷

Direction and length of the chest tube

The chest tube should ideally be aimed towards the apex of the pleural cavity for a pneumothorax or towards the diaphragm to drain fluid. However, any tube position can be effective for draining air or fluid. An effectively functioning drain should never be repositioned solely because of its position on a chest X-ray. The length of tube to be pushed inside will vary according to the patient's body habitus. However, the approximate length can always be gauged by measuring the distance from the point of insertion to the desired position on a chest X-ray. As soon as the tube is inside the pleural cavity, air/fluid/blood/pus will come into

the tube. The end of the chest tube is immediately cut to remove the cap and is connected to the tubing of the underwater seal (kept ready, as previously described; Fig. 4). Simultaneously, the physician or assistant's left hand should press the site of insertion of the chest tube with a gauze piece so as to prevent peritubal leak of pleural fluid or air entering the pleural cavity while the patient is breathing (Fig. 20). The site where the chest tube has been inserted is secured with a single purse string suture, which can also be tied around the chest tube, or two separate sutures—a purse string around the site of insertion of the chest tube and another to hold the tube in position (Fig. 21). It is important to *tie the purse string suture tightly to close the skin wound snugly around the tube* so as to prevent any peritubal leak (Fig. 22). This also prevents accidental slippage of the chest tube, which may result in pneumothorax if the holes in the tube come out.

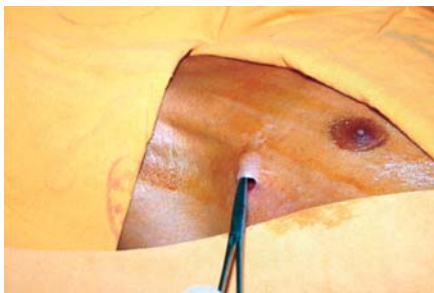


FIG 13. Creating a subcutaneous tunnel with artery forceps

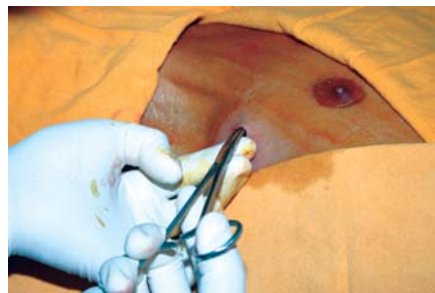


FIG 14. Chest wall puncture: The artery forceps, guarded by the fingers of the left hand, are used to split the intercostal muscles and puncture the pleura

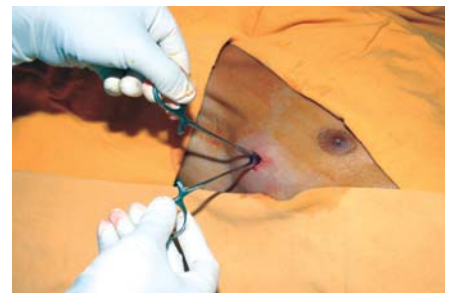

FIG 15. Dilating the tract: After entering the pleural cavity, the artery forceps are opened in the intercostal space to increase the size of the opening

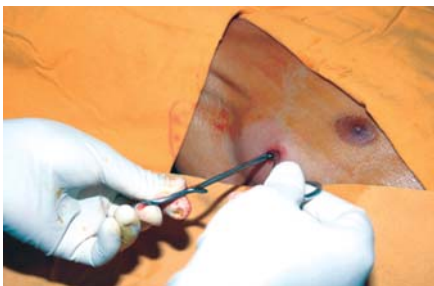


FIG 16. Dilating the tract: The artery forceps are rotated 90 degrees and again opened to increase the size of the opening

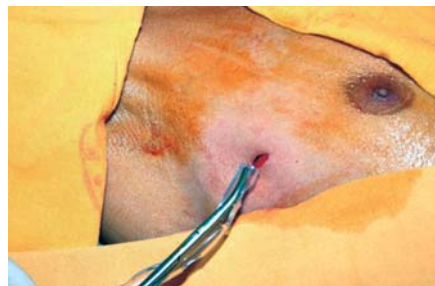

FIG 17. Grasping the chest tube: The chest tube is held by an artery forceps just proximal to its tip

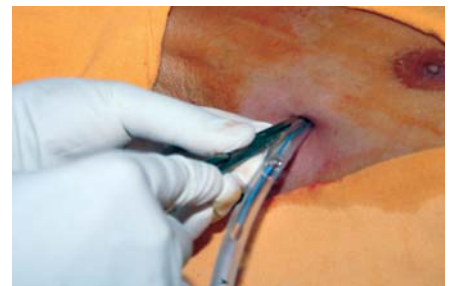

FIG 18. Inserting the tube: The tube held in the artery forceps is inserted into the pleural space. The tip of the artery forceps should be proximal to the tip of the chest tube and should never protrude beyond it

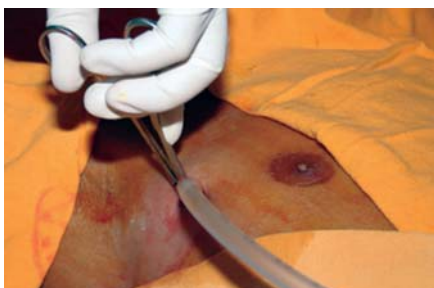

FIG 19. Guiding the chest tube: The tube is guided in the desired direction with the artery forceps and then pushed to the desired length

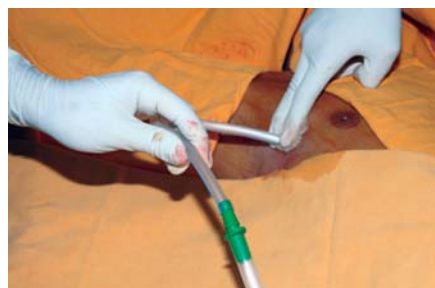

FIG 20. The assistant's finger blocking entry of air through the site of insertion of the tube

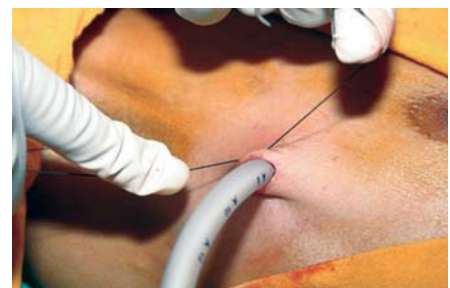

FIG 21. A purse string suture applied around the tube

Care after insertion of the chest tube

The site of insertion of the chest tube is covered with a sterile piece of gauze and adhesive tape is applied after drying the skin and using tincture benzoin, if required (Fig. 23). Loosely applied adhesive tape often leads to slippage of the chest tube. The drapes should be removed only after the dressing has been done. Any blood on the patient's body should be cleaned, and the patient's clothes and bed sheet, if soiled, should be changed (Fig. 24). The patient should be encouraged to take deep breaths and hold his/her breath at the end of inspiration to help the lung to expand. An incentive spirometer also helps in deep breathing (Fig. 25).

In case of massive pleural effusion, the fluid should be drained slowly. Not more than one litre should be drained in the first go, after which the tube should be clamped for a few hours. The fluid can then be drained at intervals of a few hours, about 500 ml at a time, with the tube clamped in between. This is necessary to prevent re-expansion pulmonary oedema, which is known to occur following sudden expansion of a lung that has been collapsed for some time due to fluid or air.^{8,9}

If the collection bottle gets filled with drained blood or fluid, it should be emptied after clamping the chest tube and in a completely sterile manner. The underwater seal bottle should always be kept upright and should be below the level of the site of insertion of the chest tube at all times. The collecting bottle's tubing should be shortened to drain directly into the bottle and there should be no loops lying on the floor, as this hampers effective drainage (Fig. 26).

The use of high-volume/low-pressure suction pumps is often advocated. While there is no consensus on when suction is to be used, it is generally recommended in non-resolving pneumothorax with partial lung expansion or following chemical pleurodesis.¹⁰ If suction is required, it should be used through the underwater seal at a pressure of 10–20 cm of H₂O. When suction is used, the patient must be nursed by appropriately trained staff as the connections must be done properly. Improper connection of the suction machine or a connected but switched off suction machine can lead to serious problems, especially in patients with an air

leak. *In patients with an air leak, the chest tube should never be clamped as this would lead to pneumothorax and collapse of the lung, and may even cause tension pneumothorax and be a threat to the patient's life.* After insertion of the chest tube, the chest should be auscultated to confirm whether there has been any improvement in air entry. A chest X-ray should always be done. The chest tube needs to be milked frequently to prevent the formation of clots in the tube and also to help empty it out completely. This is best done using a milking device, which should be available in the ward. In the absence of a milking device, it can be done by passing the tube between the fingers.

It is important to provide adequate pain relief to patients to get their maximum cooperation with respect to deep breathing. On the first day, injectable analgesics should be given (diclofenac sodium or tramadol) and thereafter, oral analgesics can be started. *Pain relief is very important and should not be neglected.*

The output from the chest tube should be monitored as required. It is generally measured at 24-hour intervals. However, in patients with bleeding, hourly monitoring may be needed. The dual-chamber bottle allows drainage of fluid to the other side, which means that the bottle needs to be emptied less frequently than a single-chamber bottle. This decreases the possibility of any breach in asepsis during emptying of the bottle. The emptying of the bottle and changing of fluid should be done carefully and by a trained person, under complete asepsis. It should never be done by an untrained person. In case a patient with a chest tube has to be discharged and looked after at home, the process should be taught to the patient or his/her attendants.

REMOVING THE CHEST TUBE: HOW AND WHEN

The following requirements must be fulfilled before planning the removal of a chest tube:^{5,11}

- The lung should be fully expanded and there should be no persisting haemothorax or pneumothorax.
- There should be no air leak.
- No fresh or altered blood should be draining from the chest tube.

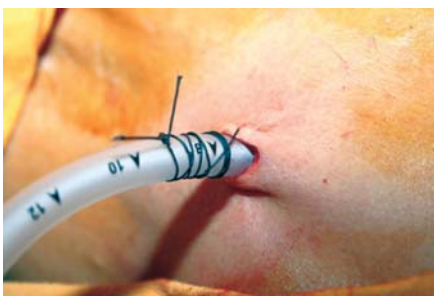


FIG 22. The chest tube secured with the suture

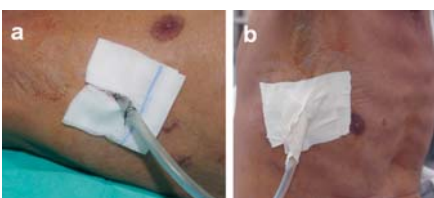


FIG 23. Sterile dressings (a) and chest tube adhesive skin tape (b) applied

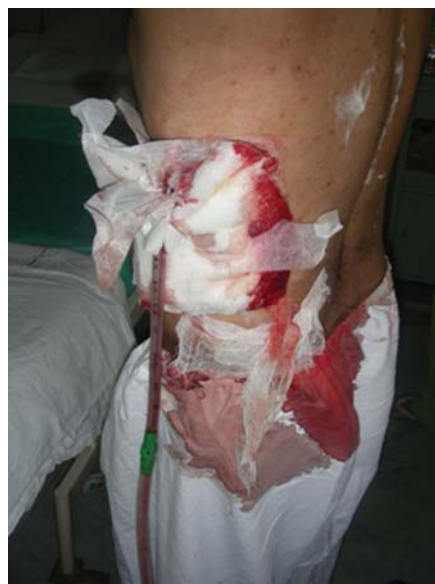

FIG 24. Effect of improper chest tube fixation: Peritubal leak with soiled dressings and clothes. This is how **not** do it

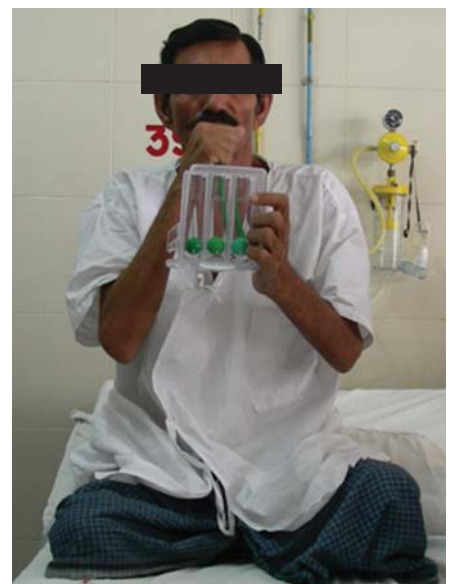

FIG 25. Incentive spirometry to help the lung expand

- The daily drainage should be <100 ml.

The process of removal of the chest tube should be explained to the patient and his/her cooperation sought. The importance of taking a deep breath and holding it at the end of inspiration should be carefully explained. The chest tube should be removed at this point and the patient asked not to breathe till the purse string suture has been tightened. It is best if at least 2 medical personnel are present when the chest tube is being removed so that when the patient holds his/her breath at the end of inspiration, one person pulls the tube out and immediately seals the wound with a piece of gauze, while the other person tightens the purse string (Fig. 27). The chest tube should not be pulled when the patient is still breathing because this will result in a pneumothorax. There is no preferred position for removal of the chest tube, which can be done in the supine or sitting position, as per the patient's comfort. After tightening the purse string suture, an occlusive dressing is applied to the site of insertion for 48 hours.

The chest should be examined clinically after removal of the tube to check whether there is adequate air entry bilaterally. A chest X-ray must be done to look for any abnormality. The patient can be allowed normal movement immediately after the chest tube has been removed, and does not need to be in hospital if the air entry is adequate and the chest X-ray taken after removal of the tube is normal.

If the X-ray taken after removal of the tube shows a pneumothorax, the course to be followed depends on the amount of the pneumothorax and the patient's condition. The chest tube should be reinserted immediately in the case of any patient who develops respiratory distress due to the pneumothorax. An asymptomatic patient should be kept under close observation, and repeated examinations and chest X-rays need to be done. Usually, the air gets reabsorbed and the lung expands slowly. If this does not occur, a chest tube should be inserted again to achieve complete expansion of the lung.

Pain relief may be required for 2–3 days after the removal of the chest tube. The suture at the site of insertion of the chest tube is removed 7–8 days after removal of the chest tube.

COMPLICATIONS AND THEIR PREVENTION

1. Injury to the neurovascular bundle in the intercostal space may occur due to wrong placement of the tube. To avoid this, the tunnel for inserting the chest tube should be made at the upper border of the lower rib in the intercostal space selected.
2. The instruments used to create the tunnel may injure the lung parenchyma. To avoid this, one should use the fingers of the opposite hand to guard the entry of the instrument into the pleural cavity, or the tip of the finger can be used to puncture the parietal pleura. The finger used for puncturing the parietal pleura should also be used to separate the lung parenchyma from the chest wall.
3. Injury to the diaphragm and consequent injury to intra-peritoneal structures may occur. To avoid this, the site of insertion of the chest tube needs to be chosen carefully.
4. Injury to the heart and a major vessel is another possible complication. To prevent this, one should follow the principle used to prevent injury to the lung parenchyma.
5. Inadvertent placement of the chest tube into the lung parenchyma causes massive bleeding. This necessitates blood transfusions and a thoracotomy may be required to control the bleeding.
6. During insertion of the chest tube in a patient on a high-pressure ventilator (especially with PEEP), it is essential to

disconnect the patient from the ventilator at the time of insertion to avoid the potentially serious complication of penetration of the lung.

7. Re-expansion pulmonary oedema due to rapid evacuation of fluid from the pleural cavity can be avoided by gradual evacuation of the pleural collection with intermittent clamping of the chest tube.
8. The formation of an empyema due to infection in the pleural cavity can be avoided by following proper aseptic techniques during the procedure and subsequent management of the drainage system.
9. Skin excoriation and inflammation can occur if the dressing is not changed on alternate days, or earlier when soiled. In infective cases, pus may trickle around the tube, leading to extensive skin infection and sloughing of the skin around the chest tube (Fig. 28). This can be avoided by changing the dressing on alternate days, using proper aseptic techniques.
10. Extensive surgical emphysema may occur in patients of pneumothorax with underlying emphysematous (bullous) lung following the insertion of a chest tube, despite a patent chest tube. The condition is usually self-limiting. The chest tube should be connected to a low-pressure




FIG 26. Length of pleural drainage tube: (a) correct length without any loop; (b) and (c) incorrect length with loops which hamper free flow of fluid from the pleural cavity to the bottle

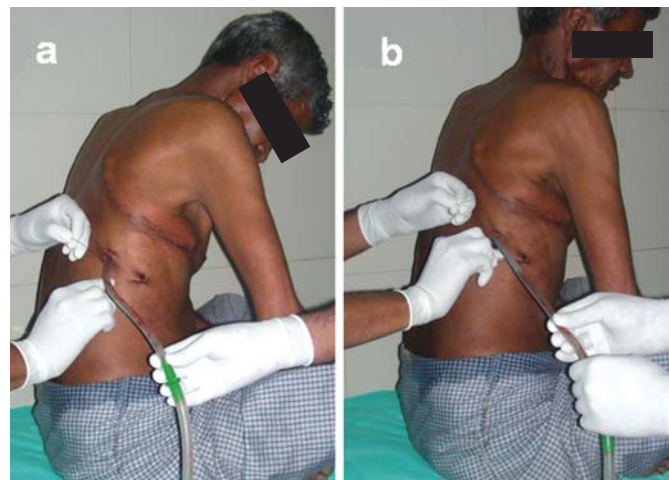


FIG 27. Removal of the chest tube: (a) purse string suture positioned; (b) assistant removing the chest tube at the end of deep inspiration

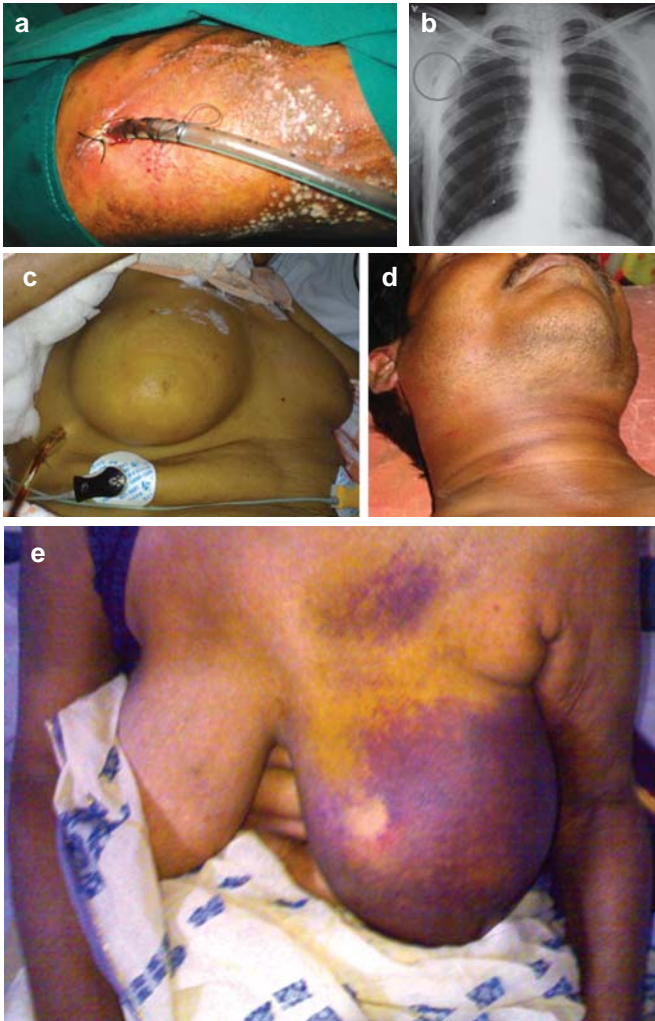

FIG 28. (a) Skin excoriation, erythema and blisters in a patient with empyema; (b) Chest X-ray showing eye of the chest tube in the subcutaneous space (circle); (c) and (d) surgical emphysema of the breast, neck, and face; (e) Haematoma and surgical emphysema of the breast in a patient with haemothorax

suction system and, if necessary, another chest tube may be inserted anteriorly in the second intercostal space on the same side.

11. Subcutaneous emphysema can also occur due to slippage of the chest tube, with the holes lying in the subcutaneous tissue. The chest tube then needs to be repositioned (Fig. 28). In a patient with a haemothorax, subcutaneous haematoma can result from incorrect placement of the chest tube if one of the hole's of the chest tube is outside the pleural cavity (Fig. 28).

ACKNOWLEDGEMENTS

We are grateful to Dr S. Bal, Department of Thoracic Surgery, Fortis Hospital, Vasant Kunj, Delhi (formerly Department of Surgery, All India Institute of Medical Sciences, New Delhi), and Professor Rajan Santosham, Department of Thoracic Surgery, Santosham Chest Hospital, Chennai, for their suggestions. We are also grateful to Drs Monika Meena, Chandan Jyoti Das and Uma Shankar Kannan for their help in the preparation of this article. We are also grateful to Mr Yogesh Kumar, Media Generalist, and the staff of Dr K.L.Wig Centre for Medical Education and Technology, All India Institute of Medical Sciences, New Delhi, for their help with the photographs and post-processing support.

No financial support has been received.

REFERENCES

- 1 Klein JS, Schultz S, Heffner JE. Interventional radiology of the chest: Image-guided percutaneous drainage of pleural effusions, lung abscess, and pneumothorax. *AJR Am J Roentgenol* 1995;**164**:581-8.
- 2 Rosenberg ER. Ultrasound in the assessment of pleural densities. *Chest* 1983;**84**:283-5.
- 3 Tomlinson MA, Treasure T. Insertion of a chest drain: How to do it. *Br J Hosp Med* 1997;**58**:248-52.
- 4 Boland GW, Lee MJ, Silverman S, Mueller PR. Interventional radiology of the pleural space. *Clin Radiol* 1995;**50**:205-14.
- 5 Miller KS, Sahn SA. Chest tubes: Indications, technique, management and complications. *Chest* 1987;**91**:258-64.
- 6 Parmar JM. How to insert a chest drain. *Br J Hosp Med* 1989;**42**:231-3.
- 7 Peek GJ, Firmin RK, Arsiwala S. Chest tube insertion in the ventilated patient. *Injury* 1995;**26**:425-6.
- 8 Trapnell DH, Thurston JG. Unilateral pulmonary oedema after pleural aspiration. *Lancet* 1970;**1**:1367-9.
- 9 Rozenman J, Yellin A, Simansky DA, Shiner RJ. Re-expansion pulmonary oedema following spontaneous pneumothorax. *Respir Med* 1996;**90**:235-8.
- 10 Harriss DR, Graham TR. Management of intercostal drains. *Br J Hosp Med* 1991;**45**:383-6.
- 11 Treasure T, Murphy JP. Pneumothorax. *Surgery* 1989;**75**:1780-6.